Feet First

SPONSORED BY Soft-Ride

The 11th NEAEP Symposium emphasized farriers and veterinarians working together for the good of the horse

STEPHANIE L. CHURCH

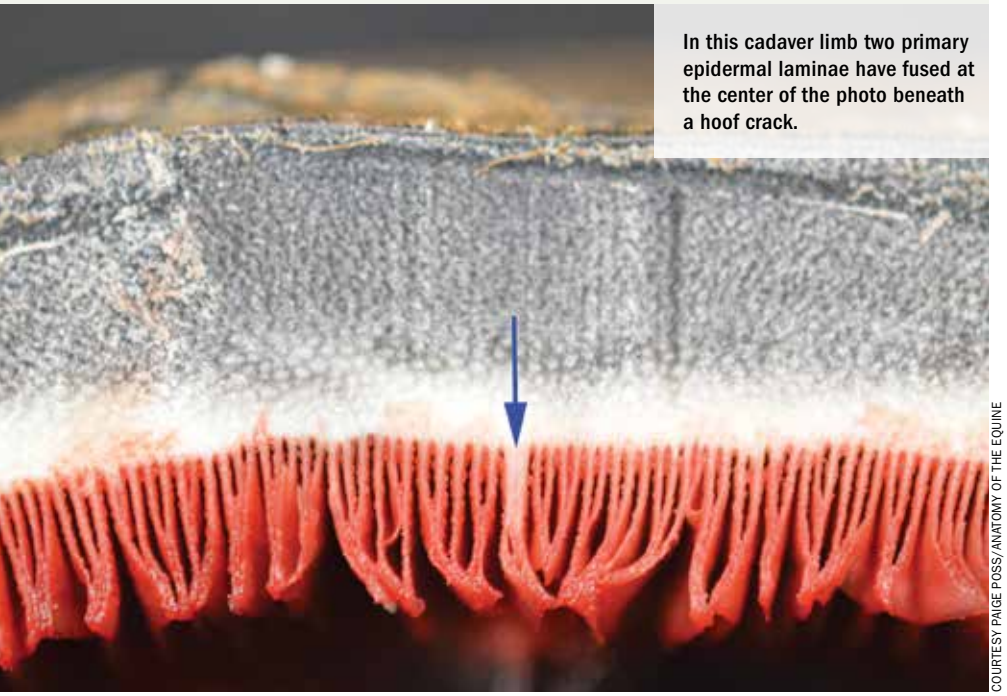

In this cadaver limb two primary epidermal laminae have fused at the center of the photo beneath a hoof crack.

COURTESY PAIGE POSS/ANATOMY OF THE EQUINE

The collaboration of two of the most important people in our horses' lives—the professional who manages their physiology and the one who manages their literal foundation—can be powerful. In practice, it can look like co-visits to the farm, phone calls to debrief after separate visits, and maybe even text message updates. Whatever form it takes, if it's functional and productive, it usually means nothing but good for the horse.

The Northeast Association of Equine Practitioners (NEAEP) aims to enable this type of relationship. In fact, the organization's mission is to encourage farriers and vets to work together for the well-being of the horse through communication and continuing education. Each year the NEAEP board curates a symposium program that covers lameness, internal medicine and reproduction, and podiatry.

The Horse attended the 11th edition, held in the fall of 2019 in Saratoga Springs, New York, and here we'll focus on what we learned in the lameness and podiatry sessions. You can find more information at TheHorse.com/2019NEAEP.

What Goes on Beneath Hoof Cracks?

Longtime hoof care provider Paige Poss has studied hoof anatomy and performed thousands of hoof dissections. What she found by cutting windows out of the hoof wall and looking at the anatomy beneath has changed her perspective on persistent hoof cracks.

Poss showed detailed images of damaged tissue to help hoof care professionals understand why it might be difficult to fix some cracks, and when and why you might want to consider calling the veterinarian for diagnostic imaging.

"Visually you will get an idea of why some of these cracks persist or reoccur," she said. "Then (you'll) gain understanding on how or even if to treat," along with how to communicate the expectations to owners. She added the disclaimer that most of her clients are owners of older horses without major athletic demands.

"I find cracks to be one of the most interesting things," she said. "Owners are often way more concerned over cracks that rarely cause lameness than they are over issues that are truly detrimental to the horse, such as major hoof imbalances. At the lower (performance) levels, cracks are generally not a problem, and a lot of these athletes do well, though horses working at speed or with greater athletic demands might struggle with those cracks.

"Everybody wants the hoof wall to be blemish-free and beautiful," she continued, "and being able to communicate that a lot of horses aren't lame on those cracks and that sometimes there is a reason that it's always going to be there is … nice (information to have) to tell owners."

Toe Cracks In a photo of this most common type of crack, Poss showed the interdigitation of the primary epidermal laminae (PELs, reaching out from the wall) and dermal laminae (reaching out from the coffin bone), which anchor the wall to the coffin bone, and vice versa. She pointed out shortened laminae and PEL fusion at the crack, along with what appeared to be displaced sole material (corium) and theorized that internal

biomechanical shifts could be irritating those laminae, encouraging them to fuse together to fortify themselves.

"You have changes to the laminae, changes to the corium, but when you look … deeper, you have clear changes to the coffin bone," she said. What isn't clear is whether the pressure of the fused, hardened PELs causes bone loss, or vice versa.

"These internal changes cause the outer hoof wall to not have good attachment in this area," she added. She likens this process to a rotten or otherwise damaged wall stud that a builder covers with new drywall. The outside looks great, but it all falls apart when you add pressure.

Good balance and a strict trimming and shoeing schedule help those internal shifts, she said.

Double Cracks Next, Poss showed a foot with two cracks, revealing how they had proceeded all the way into the white line (visible at the sole surface) and had significant coffin bone loss beneath.

"The difference between the single crack and the double crack is there seems to be more coffin bone damage behind the double cracks and more of the PELs have fused," she said.

In this hoof the epidermal laminae "spikes," as she referred to them, were significantly large and hard. "It appears they were more invasively pushing on the coffin bone and were the possible cause of the extensive bone loss," she said.

She was surprised by the extensive coffin bone damage in this hoof, but she said in her trimming practice she wouldn't have been alarmed to work on a horse with cracks like this one. "With proper hoof care, the walls usually look good," she said, "but the cracks will reappear quickly if the hoof is allowed to get long."

Quarter Cracks Next, she compared a simple quarter crack to a severe quarter crack with coffin bone damage beneath it. "There's so much tissue damage, you'd have to be very careful on how you handle (the latter crack)," she said, noting that "you're always going to be fighting this."

The hoof wall and the sensitive laminae beneath appeared to fold inward.

In many cases the farrier or vet might use a plate or wire to stabilize the crack. But Poss cautioned that more damage to the underlying structures could occur if the crack is stabilized incorrectly.

She said she'd like to photograph more of these cracks because she believes "the more we see and share, the better we can prevent or treat in the future." Some are relatively benign and straightforward, but others are tricky and cause lameness.

Poss revealed how primary epidermal laminae had fused beneath double toe cracks, creating significantly large and hard "spikes." The cracks had proceeded all the way into the white line (above) and had significant coffin bone loss beneath them (see below).

PHOTOS COURTESY PAIGE POSS/ANATOMY OF THE EQUINE

Heel Cracks Poss has never had a heel crack to dissect, so she showed a photo of one in a live horse. She theorized that such gaps are caused by pressure on soft tissue only; there's no bone involvement.

Solar Cracks She said her sole crack example appeared as if it formed due to an old abscess exit wound. As she dissected the crack, she revealed it had undermined the whole level of the sole.

Bar Cracks Poss noted that the bars are actually hoof wall but are on the bottom of the hoof on either side of the frog.

She showed a foot she perceived as unusual—it was very tall, unlike many of the feet she sees—but she didn't think much of the bar crack until she dissected it. Beneath it she found a 90-degree deviation of the laminae.

Take-Home Message Poss consistently saw significant damage beneath cracks in her dissections, both to laminae and the coffin bone, which she attributes to imbalances and lack of farrier care. She noted:

- Cracks become chronic—easy to

understand, she says, when you see the extent of bone loss behind them—and tricky to stabilize.

- Farriers and veterinarians can help owners understand that if they're really concerned about a crack, they need to get 60-degree DP (dorsoplantar) X rays.
- The onus is on the owner to stay on a 4- to 5-week trimming schedule to help keep chronic cracks under control.

COURTESY DR. ROBERT BOWKER

Solar view of a foot before starting treatment after removing shoes, and the same foot seven months later. Notice how the frog's central sulcus is shallow and broad.

Trimming to Aid Structure & Function

Robert Bowker, VMD, PhD, longtime podiatry researcher and former professor and head of the Equine Foot Laboratory at Michigan State University's (MSU) College of Veterinary Medicine, in East Lansing, never leaves home without a clear plastic ruler. At least that's the case when he's working on horses' feet and helping owners, vets, and farriers see and understand what's going on inside them and recognizing and correcting balance. Bowker described his perspectives and trimming approaches.

Reaching for the Right Ratio Bowker measures every foot, and even photos and drawings of feet shown in seminar presentations or books, to illustrate balance.

"The general guideline for the industry in balancing the hoof is approximately 50:50 (toe:heel), meaning that half of the foot is in front of a perpendicular line dropped from the center of rotation of P2 (short pastern) bone, with the other half being behind this same line," he said. "This ratio would be reasonable in most cases, if most hoof care professionals practiced it. However, most do not seem to be using this guideline, as most feet have an approximate ratio of 60:40 or even 70:30. Most people aren't measuring it but only relying on observations."

After retiring from MSU, Bowker has continued his research with other vets, farriers, and trimmers from the U.S. and beyond. He compares his findings in cadaver limbs to what he sees in live client horses, their X rays, photographs, and the like. Most cases he handles are extreme, because he usually gets calls after all traditional treatments have been exhausted.

These cases usually involve periodic lameness in both forefeet that has persisted for years, with radiographic changes in the navicular apparatus, he said (see "Navicular Issues Begin Earlier Than We Think," TheHorse.com/181721). The horses have been managed using corrective shoeing methods, "with pads or trimming with boots, etc., during this time as things are going backward." He said every single horse usually has something in common: a too-long toe and underrun heel. He believes this can be avoided with careful and correct trimming.

The mechanical forces of the 60:40 and 70:30 ratios Bowker sees put pressure on the coffin joint, which eventually leads to navicular disease, he said (see #5 in the sidebar on page 32). "Everyone knows this and understands some of the biomechanical issues with this type of foot, but few try to aggressively correct the problem," he told *The Horse*. "Many foot professionals say that such feet are not correctable, or they are only manageable. With this 'long-toe, underrun-heel' foot, the already-long toe continues to get longer. I mean the … coffin bone begins to get longer: Its conformation is gradually changing."

As the bone gets longer, the vasculature beneath it must change at the expense of the back part of the foot and the frog; the expanded toe area demands more of the foot's blood supply, routing it away from the back of the hoof, which he said is detrimental for the hoof's long-term health.

"Of all these husbandry practices, the long-toe, underrun-heel is probably the worst one that will give rise to navicular and will definitely make any bout of laminitis much worse," Bowker told *The Horse*. With this foot, "the tissues supporting and surrounding the coffin bone become compromised and the distal (bottom) end of the coffin bone gets less and less support and becomes thinner and thinner along the edges, especially the lateral (away from the midline) side of the foot. These changes will often result in pedal osteitis.

"When there's a bout of laminitis (and added) toe pressure through some rotation at the toe, the bone cannot support the weight of the horse with this peripheral thinning of the bone, and the coffin bone becomes crushed," he added. "That's the end of the horse!

"We are setting the horse up for failure by having a long toe with our trimming methods, regardless of whether the horse is shod or barefoot," he said.

Bowker trims to shorten the toe and promote caudal (toward the rear) migration of the heels to bring the central sulcus (cleft between the heels) back to the sole so it makes light contact with the ground. He said trimming with these goals can improve foot health and get the ratio to approach 40:60—allowing the caudal foot to enlarge and return to its robust health.

Tips on Trimming "You're trimming the foot to change the inside of the horse," he said. "With a long toe and underrun heels, you have to trim every three to four days until you get the toe and heels back under the horse. Then trim periods can be longer but not six to eight weeks, as that is why the foot got to becoming long."

With his cases, he gets the owner involved and gives the trimmer instructions:

- Bring the heels back to the level of the frog.
- Bevel the toe from the sole, not the dorsal hoof wall.
- The frog should kiss the ground. Too

much pressure hinders the blood supply and causes the frog to atrophy.

- You must trim inside the white line every few days to keep the toe short until the foot is back under the horse, he explained. Then you can trim every four weeks or less during the active growing season (summer).
- Ideally, the frog's central sulcus is shallow and broad. The frog stay (central ridge) is critical to foot function. Do not trim the frog. As soon as you trim it the frog starts to retract, he said, and you diminish its ability to dissipate energy.

Bowker acknowledged that many vets and farriers are leery of trimming inside the white line, and owners might be, too.

"If you have a reluctant owner, farrier, trimmer, or even veterinarian, a ruler is good, because you'll see changes in three to four days," he said, referring to "the movement of the wall, heels, and superficial tubules on the wall … . And the frog will expand to its optimal state in the ensuing days, weeks, and months.

Bowker noted that the literature says digital cushion damage is permanent but that he's been able to turn cases around; internal changes can occur if the farrier or trimmer gives the foot an opportunity, he said. A crushed cushion will repair itself with myxoid cells, "kind of a pre-stem cell," he said. "They're associated with developing adipose cells and fibrous tissues."

But, he reminded the audience, even though you might see subtle shifts in hoof balance quickly, his approach is not a quick fix—it takes time and patience.

"You can always improve the trim to improve the internal structure of the tissues. If you have a short toe, you'll have a pretty good foot," he said.

Control Your Horse's Weight & Other Ways to Prevent, Treat Laminitis

One of the best ways to prevent the devastating hoof disease laminitis is also one of the easiest, but people must realize the need and, just as importantly, act on it. Combating obesity in horses—a common contributor to insulin dysregulation, a notorious precursor to laminitis—is key to prevention, but many owners simply don't recognize their horses are overweight, says Andrew van Eps, BVSc, PhD, MACVSc, Dipl. ACVIM, associate professor of equine musculoskeletal research at the University of Pennsylvania School of Veterinary Medicine's New Bolton Center.

He spoke about evidence-based ways to prevent and treat laminitis. Besides reviewing tried-and-true, research-backed techniques, he previewed other ways we might one day avoid or manage laminitis.

In laminitis cases the laminae become damaged and inflamed. In severe cases they separate, releasing the coffin bone to rotate downward or sink. Many acutely or chronically laminitic horses must be euthanized due to the damage and relentless pain. (Visit TheHorse.com/19532 to learn what's happening on a cellular level.) Vets have identified three major forms based on the underlying causes:

- Systemic inflammatory disease (infection of the blood, or sepsis) causing acute laminitis;
- Hyperinsulinemia (an endocrinopathic, or hormone-related, issue); and
- Excessive weight-bearing on a limb.

Heavy Horses (and Ponies) In one study researchers found that 40% of owners considerably underestimated their horses' body condition (see page 40 for the right way). "There is this sort of body dysmorphism thing," said van Eps. "We need to change our definition in our minds of what constitutes normal body condition." That means not allowing equids to reach body condition scores as high as industry culture and some competition arenas have deemed acceptable—even fashionable.

The insulin dysregulation (ID)—basically, the body's inability to respond normally to insulin release—often lurking in these obese horses commonly leads to laminitis. Van Eps said the best way to manage ID in horses and ponies is to control diet and reduce obesity. "Exercise is difficult in some of these patients," he said, whether due to extreme lack of fitness or because the horse already has laminitis, making it painful to work. "Diet makes much more of a difference."

He recommends weighing the horse, then feeding hay at a rate of 1.5% of the horse's body weight per day as a simple, reliable weight loss strategy.

"(Hay) should be either tested (for nonstructural carbohydrate [NSC] levels) or soaked," he said, because these sugars can exacerbate the condition. Also consider testing NSC after soaking (he suggested Cumberland Valley Analytical Services for testing). Supplement the hay with a ration balancer to ensure vitamin and mineral needs are met.

Keep in mind not all horses with ID

Bowker: What Goes Awry

Here are some insights and tips Robert Bowker, VMD, PhD, shared on the normal equine foot and what goes wrong with typical husbandry practices:

1. The foot is extremely adaptable. Conformation is a point in time. This can be corrected and improved if the foot is given the opportunity.
2. The foot adapts to the environment (trimming, shoeing, loading, ground surface, moisture, etc.), but the biggest environmental factors are the hoof care professional and the trim. "They can (cause) major environmental effects and greater biomechanical changes in a brief time period," he said. "These changes affect the internal tissues (which) respond each time the foot is trimmed."
3. All feet are different, even in the same horse and in the same pair of legs.
4. Long toes and underrun heels are ubiquitous, and much of the horse industry accepts them as normal. "I have several thousand sagittal photos of feet … (only) one of them is (balanced) 50:50 front to back," he said.
5. As the toe and coffin bone lengthen, Bowker says the bone remodels internally as it attempts to support the longer toe; the bone becomes more porous due to more movement between the bone and wall. "This increased porosity is not beneficial," he told *The Horse*.
6. Navicular bone movement up and down, due to mechanical changes, damages the deep digital flexor tendon and insertion ligaments of the distal sesamoidean impar ligament.
7. With a long toe and underrun heels, the bottom end of the short pastern bone (P2) changes shape, too. It starts out symmetrical in its articulation with the coffin bone. But current standard trimming methods alter the biomechanics, Bowker says, as the end becomes asymmetrical. "With the gradually increasing length of the coffin bone, chip fractures begin to appear on the navicular bone, and they can appear (at any age)," he told *The Horse*. "Many associate these fractures with navicular syndrome. If you have a short toe, you don't have that."

are obese (or even overweight) and, also, that horses with ID might have laminitis without obvious lameness. Van Eps said that in one study researchers found radiographic evidence of laminitis in 76% of horses presented for pituitary pars intermedia dysfunction (PPID, aka equine Cushing's disease), but half of them had not shown signs of foot pain, and laminitis wasn't recognized by the owners. Pituitary pars intermedia dysfunction leads to an overproduction of hormones such as adrenocorticotropic hormone (ACTH) and cortisol, and affected horses can have regional fat deposits and experience muscle wasting, among other signs, but they aren't generally obese.

"Our goal for now (to prevent endocrinopathic laminitis) is to target ID," he said. "Diagnose them early, because this type of laminitis is often well-advanced before we see any outward clinical signs."

Van Eps prefers to test plasma ACTH concentration for diagnosing PPID: either resting (baseline) or after thyrotropin-releasing hormone (TRH) stimulation (a little more sensitive). With this test vets look for overproduction of ACTH, which the pituitary gland—enlarged or affected by a tumor in PPID horses—normally makes in relatively small amounts to control adrenal gland function. Vets must remember seasonal reference ranges when assessing results.

After starting the confirmed-PPID horse on Prascend (the FDA-approved pergolide drug), "you need to test them a month later and then at least once a year to see if their ACTH is under control, because you can't control their laminitis if there's an underlying uncontrolled endocrinopathy."

Van Eps recommends using the oral sugar test (OST) to check for equine metabolic syndrome, another form of ID. This involves collecting a blood sample, followed by administering light corn syrup orally, and collecting another sample 60 to 90 minutes later. In a new study van Eps' group showed that the OST can be performed immediately after the TRH stimulation test as a combined protocol without affecting the results, and this is best way to test for ID and PPID in one visit.

He welcomes vets to contact him with any questions about interpreting results.

Indeed, metabolically, there's a "type" of horse or pony that is prone to developing laminitis, but you can't always identify one by looking at him. Researchers are working to identify predictors in the genes, said van Eps.

COURTESY CHRISTINA WEESE

Western College of Veterinary Medicine reseracher Dr. Julia Montgomery is collaborating with an engineering firm to create a harness to help horses recover from limb injuries. Dr. Andrew van Eps of Penn Vet said it could be helpful for treating supporting limb laminitis cases.

"There's a good chance in the future that we're going to have some genetic markers and some genetic tests," he said, "and potentially breed this out (of the horse population)."

> "We are likely to see more medication options become available for horses and ponies with ID in the coming years."
>
> DR. ANDREW VAN EPS

In terms of medical treatments for ID, van Eps said there are now options that might suit different horses and ponies, and owners should always consult their vet. "Levothyroxine may be a useful adjunct to weight loss and can help to improve ID," he told *The Horse*. "Supplements containing polyphenols such as resveratrol may help to improve ID; however, there is very limited evidence for this in horses at this stage.

"Metformin can be useful in horses and ponies to reduce the insulin response to feeding if given in a targeted way shortly before meals/turnout," he added. "There are other options on the horizon for targeting ID, including a recent paper with some exciting preliminary evidence on a drug class that helps to control insulin by enhancing the clearance of glucose from the blood by the kidneys. We are likely to see more medication options become available for horses and ponies with ID in the coming years."

Four on the Floor Another type of horse predisposed to laminitis is one that hasn't been bearing weight evenly on all four limbs, usually because of a severe injury. Metabolically and mechanically, something happens that causes laminar damage in the supporting limb.

Van Eps says to prevent laminitis in these horses, blood must perfuse the tiny capillaries of the foot in the supporting limb. The best way to improve digital capillary perfusion is to cycle weight off and on that limb. That's not easy to accomplish in a horse that's shifting its weight to be comfortable, however.

"We need to improve limb load cycling in order to improve perfusion," said van Eps. "We've done some work trying to improve perfusion using various means in the limb under load, and it doesn't appear possible. It looks like we have to provide some sort of load relief to do that."

He said vets in Canada are developing

a robotic sling that provides individual limb load relief rather than unloading all limbs as existing slings do.

Another approach he and other researchers have taken to unload the supporting limb is forced recumbency (lying down): putting horses in a stall or corral with a low ceiling or roof so they cannot stand for controlled periods. "They very calmly accept their lot," he said of horses in which his colleagues have tested this approach for up to three days. Van Eps said the approach "might sound ridiculous," but knowing what he knows about laminitis, he feels it might be useful either as a preventive or in acute cases.

Other approaches involve pain relief. Administering systemic analgesia such as opioids can make horses sluggish, causing them to move less when, again, limb cycling is what's desirable. Regional techniques—blocking the injured limb—might be the better answer.

It takes immersion in an ice water slurry to cool the interior of the foot to the extent that laminitis can be averted or helped

"We need to get them moving," said van Eps, but "recognizing when they are not moving enough (and laminitis is an impending threat) is half the challenge."

He said for this effort researchers need technology to measure not only heart rate and movement in supporting-limb-laminitis-prone horses—something existing wearables do—but also subtle offloads of the limb; pedometers on limbs just count the steps and tend to overestimate.

While we wait for technology to become available, said van Eps, "the best thing we can probably do for horses at high risk of supporting-limb laminitis is controlled walking or static load cycling, as often as every two to four hours. Forcing them or encouraging them to take some steps or at least unload that limb. I think there's some development in that space that's likely to be useful in actually getting rid of this problem."

Preventing or Managing Acute Laminitis: Act Fast, Seek Ice Water Immersion

No matter the laminitis trigger in a horse, the response is the same: Don't delay. Chill the feet. Provide pain relief.

"We can prevent laminitis if we get it early enough, and even in clinical situations it has been shown that cooling the feet can help prevent laminitis in horses with colitis," he said.

Van Eps explained the original rationale behind cooling limbs in horses at risk of or experiencing acute laminitis: blood vessel vasoconstriction in the feet, which would limit delivery of blood-borne laminitis trigger factors ranging from endotoxin or bacteria to other compounds within the body. He cited research in which cooling scalps of human chemotherapy patients inhibited hair loss; constricting the vessels is thought to limit both chemo delivery to the follicle and follicle activity.

"Cold, though, has these really profound effects on limiting metabolic activity and limiting inflammation," he said, as well as on analgesia—reduced sensation—and enzymatic activity.

Doctors have also used cooling extensively in children with hypoxic ischemic encephalopathy (oxygen deprivation to the brain), he said—a similar condition to that seen in foals with periparturient asphyxia (so-called "dummy foals").

Van Eps said there are also some laminitis cooling parallels with acute lung injury in systemic inflammatory response syndrome (SIRS, or sepsis) research in humans. "In rodent models of this important human disease, you end up with reduced white blood cells in the lungs of rats that are cooled, indicating that cooling can reduce the damage and inflammatory response in organs of septic animals."

In septic horses at risk of laminitis, he's used microdialysis probes to check glucose metabolism in cooled feet, finding indicators of energy metabolism interference in septic horses but not in septic horses whose feet were iced. "Cooling has a profound effect on slowing the metabolism of glucose in the feet, and there is some evidence that (cryotherapy) may be preventing a secondary energy crisis," he said, "which may be one way it helps slow laminitis progression in these horses."

Even in horses with signs of acute laminitis, it's not too late to cool the feet and help reduce disease progression. But "the hoof itself buffers heat remarkably," he said, "so it's a real challenge."

Hoof surface temperature is not a good indicator of the temperature inside the capsule; the wall might feel quite cold to touch with some cooling approaches, but it takes immersion in an ice water slurry to cool the interior of the foot to the extent that laminitis can be averted or helped.

"Ice packs are convenient, and we are hopeful that with the right apparatus they might be useful," he said. "But ice pack systems in our testing thus far have not been near as effective as ice and water immersion at cooling the actual lamellae deeper in the foot."

Van Eps said he did some research with custom-built ice compression systems, which were very effective but expensive. "That and the ice water immersion were the most effective means," he said.

"The evidence we have suggests that the temperature within the lamellar tissue below the hoof wall needs to be less than 10 degrees C (50 degrees F)—that is the temperature that has proved effective in the experimental trials we have done.

"I do think that ice water immersion is still the way to go," he added, "and there are commercial systems out there that are designed to allow constant ice and water immersion and that achieve similar temps to what we get experimentally."

He recommends starting ice water immersion of the hooves of any horse immediately at risk for developing acute laminitis, such as horses with colitis, proximal enteritis, and grain overload, prior to clinical signs developing. Keep the limb immersed for as long as needed—he says horses have tolerated clinical ice water immersion for up to five days.

When do you stop icing the feet? "Use abatement of primary disease as a marker for cessation," he said. "Along with resolution of fever and other signs of endotoxemia, blood tests such as SAA (serum amyloid A) are ways of determining if the systemic inflammation has subsided."

Possible untoward effects of cryotherapy are increased blood viscosity, enhanced microvascular thrombus (clot) formation, impaired coagulation, enhanced edema (fluid swelling) at lower temperatures, and immunosuppression. But the only adverse effects vets have seen are dermatitis and (rarely) frostbite when ice has been in contact with the skin for too long.